

Review of Literature: COVID-19 Outbreaks Association With Mucormycosis In India & Worldwide

Satpinder Kaur¹, Vishal salhotra²

¹Assist prof, Dept of ENT

²Dept of ENT

^{1,2} The White Medical College & Hospital , Pathankot, Punjab-145001, India

Abstract- *Coronavirus disease 2019 (COVID-19) caused an unprecedented global health crisis and was associated with multiple secondary infections, among which mucormycosis emerged as one of the most severe opportunistic fungal diseases. During the second wave of the pandemic, especially in India, a dramatic rise in COVID-19 associated mucormycosis (CAM) cases was reported. CAM predominantly affected patients with uncontrolled diabetes mellitus, prolonged corticosteroid therapy, immune dysregulation, hypoxia, and prolonged hospitalization. Rhino-orbito-cerebral mucormycosis was the most common presentation in India, whereas pulmonary mucormycosis was more frequently observed in Western countries. The present review summarizes the epidemiology, etiopathogenesis, risk factors, clinical manifestations, diagnosis, treatment, and preventive strategies related to CAM globally with special emphasis on India. Literature from peer-reviewed journals, WHO reports, PubMed, and Google Scholar was reviewed to understand the burden and outcomes of this emerging fungal infection. The findings indicate that irrational steroid use, poor glycemic control, endothelial dysfunction, and impaired immunity during COVID-19 significantly contributed to the outbreak. Early diagnosis, surgical debridement, prompt antifungal therapy, and management of comorbid conditions remain essential for reducing mortality. The review also highlights the need for awareness among healthcare professionals regarding rational steroid use and early recognition of warning symptoms.*

Keywords: COVID-19, Mucormycosis, Black Fungus, Rhino-orbito-cerebral mucormycosis, Diabetes mellitus, Corticosteroids, Opportunistic fungal infection, SARS-CoV-2, Antifungal therapy

I. INTRODUCTION

Mucormycosis is an aggressive and life-threatening fungal infection caused by fungi belonging to the order Mucorales. The disease usually affects immunocompromised individuals and is characterized by rapid angioinvasion,

thrombosis, and tissue necrosis. Before the COVID-19 pandemic, mucormycosis was considered relatively rare. However, during the COVID-19 outbreak, especially in India, there was a sudden and alarming increase in the number of mucormycosis cases. The condition became widely known as “black fungus” in the media due to the black necrotic tissue observed clinically.

COVID-19 associated mucormycosis (CAM) emerged as a major challenge during the second wave of the pandemic. India reported the highest burden of CAM worldwide, accounting for thousands of cases within a short duration. Multiple factors contributed to this surge, including uncontrolled diabetes mellitus, widespread use of corticosteroids, prolonged oxygen therapy, immune dysregulation, and prolonged hospitalization. Rhino-orbito-cerebral mucormycosis was the most commonly reported presentation, often resulting in facial deformity, orbital invasion, vision loss, and intracranial complications.

Studies suggested that COVID-19 itself contributed to endothelial dysfunction, lymphopenia, increased ferritin levels, and impaired phagocytic activity, thereby creating a favorable environment for fungal proliferation. Delayed diagnosis often resulted in high morbidity and mortality. Early identification and prompt management became essential to improve outcomes. [1,2]

Epidemiological Data in India and Other Countries

India reported the highest number of COVID-19 associated mucormycosis (CAM) cases globally during the second wave of the pandemic in 2021. According to government estimates, more than 47,000 CAM cases were reported in India by July 2021, with the majority originating from states such as Maharashtra, Gujarat, Rajasthan, and Delhi. The prevalence of mucormycosis in India before the pandemic was already nearly 70 times higher than that reported in developed countries due to the high burden of uncontrolled diabetes mellitus. Studies from India revealed

that approximately 80%–90% of CAM patients had diabetes mellitus, while nearly 75% had received corticosteroid therapy during COVID-19 management. Rhino-orbito-cerebral mucormycosis represented the most common presentation in India. Mortality rates ranged between 30% and 50%, especially among patients with delayed diagnosis and intracranial extension. In contrast, countries such as the United States, France, Italy, and the United Kingdom reported relatively lower numbers of CAM cases. Pulmonary mucormycosis was more frequently observed in Western countries, particularly among critically ill patients admitted to intensive care units. European studies suggested mortality rates of 40%–80% in pulmonary and disseminated mucormycosis due to severe respiratory failure and delayed diagnosis. Iran, Egypt, and Turkey also reported increasing CAM cases during the pandemic, mainly among diabetic and immunocompromised individuals. Global literature demonstrated that regions with higher prevalence of diabetes mellitus and indiscriminate steroid use experienced greater burden of CAM. Improved awareness, early diagnosis, and strict metabolic control were associated with better outcomes in developed healthcare settings.

The etiopathogenesis of COVID-19 associated mucormycosis is multifactorial. Mucorales fungi are ubiquitous in the environment and are commonly present in soil, decaying organic matter, and air. Infection usually occurs through inhalation of fungal spores into the nasal cavity or lungs. In healthy individuals, innate immune mechanisms prevent fungal invasion. However, immunocompromised states significantly increase susceptibility.

Etiopathogenesis:

COVID-19 leads to immune dysregulation by reducing CD4+ and CD8+ T-cell counts, impairing neutrophil function, and causing cytokine imbalance. Hyperglycemia and diabetic ketoacidosis create an acidic environment favorable for fungal growth. Elevated serum iron and ferritin levels during severe COVID-19 further promote fungal proliferation.

Corticosteroid therapy suppresses immune responses and worsens hyperglycemia, thereby increasing the risk of secondary fungal infections.

The fungi invade blood vessels causing thrombosis, ischemia, and tissue necrosis. In rhino-orbito-cerebral mucormycosis, the infection spreads from the nasal mucosa to paranasal sinuses, orbit, and brain. Pulmonary mucormycosis occurs due to inhalation of spores into the lungs and is more common among critically ill or ventilated patients.

Disseminated disease may involve multiple organs and carries a very poor prognosis. [3,4]

• Aim and Objectives

The present review was undertaken with the following objectives:

1. To study the association between COVID-19 and mucormycosis.
2. To review the epidemiology of CAM in India and worldwide.
3. To identify major risk factors contributing to the outbreak.
4. To analyze etiopathogenesis and clinical manifestations.
5. To review diagnostic modalities and treatment strategies.
6. To summarize preventive measures and future recommendations.

II. REVIEW OF LITERATURE

Several studies conducted during the COVID-19 pandemic highlighted the dramatic rise in mucormycosis cases. Pal et al. reported that India contributed the majority of global CAM cases and identified diabetes mellitus and corticosteroid use as the most common associated factors. [5] Another systematic review by Singh et al. analyzed over 100 cases and observed that rhino-orbito-cerebral involvement was the predominant presentation in India. [6]

John et al. described uncontrolled diabetes mellitus and severe COVID-19 as the “perfect storm” for mucormycosis development. They suggested that steroid-induced hyperglycemia and immune suppression played major roles in fungal invasion. [7] Honavar emphasized that delayed diagnosis was associated with poor prognosis and stressed the importance of early recognition of warning symptoms such as facial pain, orbital swelling, and black nasal discharge. [8]

Global studies also reported pulmonary mucormycosis among critically ill COVID-19 patients requiring intensive care support. Skiada et al. highlighted that pulmonary involvement was associated with high mortality rates due to delayed diagnosis and severe respiratory compromise. [9] Research conducted in Europe and the United States reported lower incidence compared to India, which may be due to lower prevalence of uncontrolled diabetes and more regulated corticosteroid use.

Studies also examined the role of iron metabolism and endothelial dysfunction in CAM. Elevated ferritin levels, endothelial injury, and cytokine storm associated with severe

COVID-19 were found to contribute significantly to fungal proliferation. [10] Researchers emphasized the need for rational corticosteroid use and strict glycemic control to reduce the incidence of CAM.

The literature consistently demonstrates that CAM represents a multifactorial opportunistic infection triggered by host immune dysfunction, metabolic disturbances, and inappropriate therapeutic practices during the pandemic.

III. MATERIAL AND METHODS

This review article was prepared using literature obtained from PubMed, Google Scholar, Scopus, WHO publications, and peer-reviewed journals published between 2020 and 2025. Keywords used for literature search included “COVID-19 associated mucormycosis,” “black fungus,” “rhino-orbito-cerebral mucormycosis,” “SARS-CoV-2 fungal infections,” and “mucormycosis in India.”

Relevant observational studies, systematic reviews, case reports, and review articles were included. Articles discussing epidemiology, pathogenesis, risk factors, clinical presentation, diagnosis, treatment, and outcomes of CAM were analyzed. Duplicate studies and unrelated fungal infections were excluded. Data were organized and summarized under thematic headings for better understanding and interpretation.

Clinical Features

Clinical manifestations of CAM depend upon the site of involvement and severity of disease. Rhino-orbito-cerebral mucormycosis commonly presents with facial pain, facial swelling, headache, nasal blockage, black nasal discharge, toothache, palatal ulceration, and orbital symptoms such as ptosis, proptosis, diplopia, and vision loss. Cerebral extension may lead to altered sensorium, seizures, cranial nerve palsies, and coma.

Pulmonary mucormycosis presents with fever, cough, chest pain, dyspnea, and hemoptysis. Gastrointestinal mucormycosis may present with abdominal pain, vomiting, gastrointestinal bleeding, or perforation. Cutaneous mucormycosis is characterized by necrotic skin lesions following trauma or burns.

The disease progresses rapidly due to angioinvasion and tissue necrosis. Therefore, clinicians must maintain a high index of suspicion among post-COVID patients with diabetes or steroid exposure presenting with facial or respiratory symptoms. [8,9]

Diagnosis

Diagnosis of mucormycosis requires clinical suspicion supported by radiological and microbiological evidence. Imaging studies such as CT scan and MRI help determine the extent of disease involvement. MRI is particularly useful for assessing orbital and intracranial extension.

Direct microscopy using potassium hydroxide (KOH) mount demonstrates broad, ribbon-like, aseptate fungal hyphae. Histopathological examination confirms tissue invasion and angioinvasion. Fungal culture helps identify species but may require several days.

Laboratory investigations often reveal hyperglycemia, elevated inflammatory markers, and metabolic acidosis in diabetic patients. Early diagnosis is critical because delayed treatment significantly increases mortality. [5,10]

Management

Management of CAM requires a multidisciplinary approach involving physicians, otorhinolaryngologists, ophthalmologists, neurologists, microbiologists, and surgeons. The main principles of treatment include early diagnosis, reversal of underlying risk factors, surgical debridement, and antifungal therapy.

Liposomal Amphotericin B is considered the drug of choice for initial therapy. Posaconazole and Isavuconazole may be used as step-down or salvage therapy. Surgical debridement of necrotic tissue is often essential to control disease progression. In advanced rhino-orbito-cerebral disease, orbital exenteration may be required to save life.

Strict glycemic control and judicious corticosteroid use are extremely important preventive measures. Early initiation of antifungal therapy significantly improves survival rates. [6,7]

Observation and Results

The literature review revealed that India accounted for the majority of global CAM cases reported during the second wave of COVID-19. Most affected patients had uncontrolled diabetes mellitus and history of corticosteroid therapy. Rhino-orbito-cerebral mucormycosis was the predominant clinical presentation in India, while pulmonary involvement was more commonly observed in Western countries.

Mortality rates ranged from 30% to 80% depending

upon site of involvement, delay in diagnosis, and associated comorbidities. Cerebral extension and disseminated disease were associated with very poor outcomes. Studies consistently demonstrated that early surgical intervention and antifungal therapy improved prognosis. [5,8]

Discussion

The sudden rise of CAM during the COVID-19 pandemic represented a major public health challenge, especially in India. Multiple interacting factors contributed to the outbreak, including widespread diabetes mellitus, irrational steroid use, immune dysfunction, prolonged hospitalization, and environmental exposure to fungal spores.

India’s high prevalence of diabetes mellitus significantly increased susceptibility to mucormycosis. During the pandemic, corticosteroids were extensively used to reduce inflammation in severe COVID-19 cases. However, inappropriate steroid administration among mild cases and prolonged use resulted in hyperglycemia and immune suppression, creating ideal conditions for fungal proliferation.

COVID-19 itself contributed to endothelial dysfunction, cytokine storm, elevated ferritin levels, and lymphopenia. These alterations impaired host defenses and enhanced angioinvasion by fungi. Overburdened healthcare systems, delayed diagnosis, and inadequate awareness further worsened outcomes during the pandemic peak.

The review also highlights the importance of early warning signs such as facial pain, orbital swelling, toothache, nasal crusting, and visual disturbances. Timely recognition followed by aggressive surgical and antifungal management can significantly reduce mortality. Public health awareness regarding rational steroid use and diabetes control remains essential to prevent future outbreaks. [1,7,10]

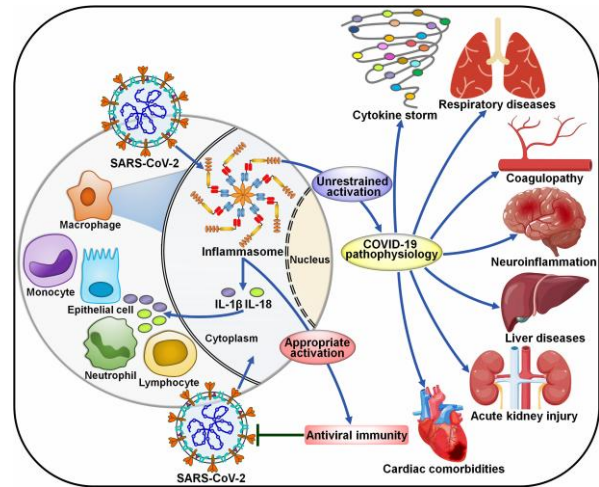
IV. CONCLUSION

COVID-19 associated mucormycosis emerged as one of the most serious opportunistic fungal infections during the pandemic. India experienced the highest burden globally due to widespread diabetes mellitus, steroid use, and healthcare challenges. The disease demonstrated rapid progression and high mortality if not diagnosed early.

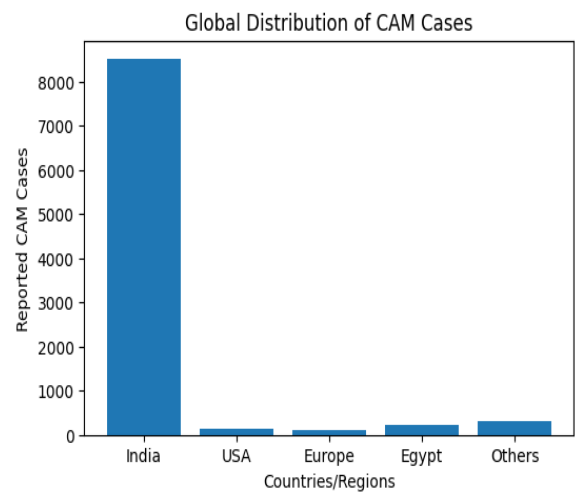
The literature strongly indicates that strict glycemic control, rational corticosteroid use, early diagnosis, prompt antifungal therapy, and surgical debridement are the cornerstones of management. Awareness among healthcare professionals and the general public is essential to reduce

morbidity and mortality associated with CAM. Further multicentric research is required to improve understanding of epidemiology, prevention, and therapeutic strategies for future outbreaks.

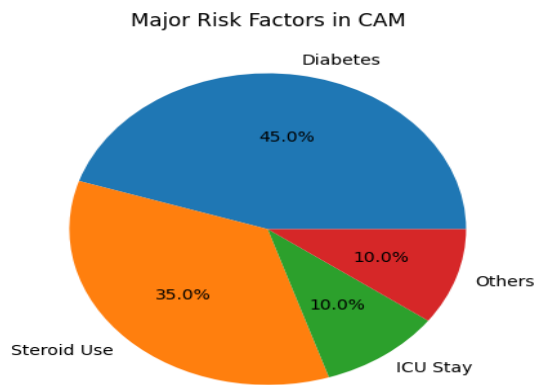
Diagram of etiopathogenesis:



• **Bar Diagram**



• **Pie Diagram**



- **Source of support: None**
- **Conflict of interest : None**

REFERENCES

- [1] John TM, Jacob CN, Kontoyiannis DP. When uncontrolled diabetes mellitus and severe COVID-19 converge: the perfect storm for mucormycosis. *Journal of Fungi*. 2021.
- [2] World Health Organization. Mucormycosis factsheet and COVID-19 associated fungal infection guidelines. WHO; 2021.
- [3] Pal R, Singh B, Bhadada SK, et al. COVID-19 associated mucormycosis: An updated systematic review. *Mycoses*. 2021.
- [4] Singh AK, Singh R, Joshi SR, Misra A. Mucormycosis in COVID-19: A systematic review. *Diabetes & Metabolic Syndrome*. 2021.
- [5] Honavar SG. Code mucor: Guidelines for diagnosis and management of rhino-orbito-cerebral mucormycosis in COVID-19 patients. *Indian Journal of Ophthalmology*. 2021.
- [6] Skiada A, et al. Challenges in the diagnosis and treatment of mucormycosis. *Medical Mycology*. 2020.
- [7] Prakash H, Chakrabarti A. Global epidemiology of mucormycosis. *Journal of Fungi*. 2019.
- [8] Almyroudi MP, et al. Clinical phenotypes of COVID-19 associated mucormycosis. *Diagnostics*. 2022.
- [9] Cornely OA, et al. Global guideline for the diagnosis and management of mucormycosis. *Lancet Infectious Diseases*. 2019.
- [10] Sen M, Honavar SG, Sharma N, et al. COVID-19 and mucormycosis: Eye manifestations and outcomes. *Indian Journal of Ophthalmology*. 2021.
- [11] Garg D, Muthu V, Sehgal IS, et al. Coronavirus disease associated mucormycosis in India: A case series and systematic review. *Clinical Microbiology and Infection*. 2021.
- [12] Mehta S, Pandey A. Rhino-orbital mucormycosis associated with COVID-19. *Cureus*. 2020.
- [13] Werthman-Ehrenreich A. Mucormycosis with orbital compartment syndrome in a patient with COVID-19. *American Journal of Emergency Medicine*. 2021.
- [14] Patel A, Agarwal R, Rudramurthy SM, et al. Multicenter epidemiologic study of coronavirus disease associated mucormycosis, India. *Emerging Infectious Diseases*. 2021.
- [15] Chakrabarti A, Singh R. Mucormycosis in India: Unique features. *Mycoses*. 2014.
- [16] Spellberg B, Edwards J Jr, Ibrahim A. Novel perspectives on mucormycosis. *Clinical Microbiology Reviews*. 2005.
- [17] Roden MM, Zaoutis TE, Buchanan WL, et al. Epidemiology and outcome of zygomycosis. *Clinical Infectious Diseases*. 2005.
- [18] Ibrahim AS, Spellberg B, Walsh TJ, Kontoyiannis DP. Pathogenesis of mucormycosis. *Clinical Infectious Diseases*. 2012.
- [19] Lanternier F, Dannaoui E, Morizot G, et al. A global analysis of mucormycosis in France. *Clinical Infectious Diseases*. 2012.
- [20] Skiada A, Pavleas I, Drogari-Apiranthitou M. Epidemiology and diagnosis of mucormycosis. *Journal of Fungi*. 2020.
- [21] Buil JB, van Zanten ARH, Bentvelsen RG, et al. Case series of COVID-19 associated pulmonary aspergillosis and mucormycosis. *Journal of Critical Care*. 2021.
- [22] Hoenigl M, Seidel D, Carvalho A, et al. The emergence of COVID-19 associated mucormycosis. *Lancet Microbe*. 2022.
- [23] Ravani SA, Agrawal GA, Leuva PA, et al. Rise of the phoenix: Mucormycosis in COVID-19 times. *Indian Journal of Ophthalmology*. 2021.
- [24] Sen M, Lahane S, Lahane TP, et al. Mucor in a viral land: A tale of two pathogens. *Indian Journal of Ophthalmology*. 2021.
- [25] Dilek A, Ozaras R, Ozkaya S, et al. COVID-19 associated mucormycosis: Case report and systematic review. *Travel Medicine and Infectious Disease*. 2021.
- [26] Maini A, Tomar G, Khanna D, et al. Sino-orbital mucormycosis in a COVID-19 patient: A case report. *International Journal of Surgery Case Reports*. 2021.
- [27] Moorthy A, Gaikwad R, Krishna S, et al. SARS-CoV-2, uncontrolled diabetes and corticosteroids—an unholy trinity in invasive fungal infections. *Indian Journal of Critical Care Medicine*. 2021.
- [28] Bhattacharyya A, Sarma P, Sharma DJ, et al. Rhino-orbital cerebral mucormycosis in COVID-19. *Indian Journal of Pharmacology*. 2021.
- [29] Baldin C, Ibrahim AS. Molecular mechanisms of mucormycosis. *Current Opinion in Microbiology*. 2017.

- [30] Kontoyiannis DP, Lewis RE. How I treat mucormycosis. *Blood*. 2011.
- [31] Rammaert B, Lanternier F, Zahar JR, et al. Healthcare-associated mucormycosis. *Clinical Infectious Diseases*. 2012.
- [32] Skiada A, Lass-Florl C, Klimko N, et al. Challenges in the diagnosis and treatment of mucormycosis. *Medical Mycology*. 2018.
- [33] Petrikkos G, Tsioutis C. Recent advances in the pathogenesis of mucormycosis. *Clinical Therapeutics*. 2018.
- [34] Rudramurthy SM, Hoenigl M, Meis JF, et al. EMM/ISHAM recommendations for clinical management of COVID-19 associated mucormycosis. *Lancet Infectious Diseases*. 2021.
- [35] Nehara HR, Puri I, Singhal V, et al. Rhinocerebral mucormycosis in COVID-19 patients. *Journal of Family Medicine and Primary Care*. 2021.
- [36] Jeong W, Keighley C, Wolfe R, et al. The epidemiology and clinical manifestations of mucormycosis. *Clinical Microbiology and Infection*. 2019.
- [37] Gangneux JP, Dannaoui E, Fekkar A, et al. Fungal infections in mechanically ventilated COVID-19 patients. *Journal of Fungi*. 2022.
- [38] Singh Y, Ganesh V, Kumar S, et al. Coronavirus disease associated mucormycosis from a tertiary care hospital in India. *Mycoses*. 2021.
- [39] Sharma S, Grover M, Bhargava S, et al. Post coronavirus disease mucormycosis: A deadly addition. *Indian Journal of Ophthalmology*. 2021.
- [40] Arana C, Cuevas-Ramirez RE, Xipell M, et al. Mucormycosis associated with COVID-19 in hospitalized patients. *Journal of Fungi*. 2021.
- [41] Kumar M, Sarma DK, Shubham S, et al. Mucormycosis in COVID-19 pandemic: Risk factors and linkages. *Current Research in Microbial Sciences*. 2021.
- [42] Pasero D, Sanna S, Liperi C, et al. A challenging complication following SARS-CoV-2 infection. *IDCases*. 2021.
- [43] Fouad YA, Abdelaziz TT, Askoura A, et al. Spike in rhino-orbital-cerebral mucormycosis cases during COVID-19 pandemic. *Journal of Craniofacial Surgery*. 2021.
- [44] Hanley B, Naresh KN, Roufousse C, et al. Histopathological findings in COVID-19 cases. *Lancet Microbe*. 2020.
- [45] Gangneux JP, Bougnoux ME, Dannaoui E, et al. Invasive fungal diseases during COVID-19. *Journal de Mycologie Médicale*. 2020.
- [46] Lee FYW, Mossad SB, Adal KA. Pulmonary mucormycosis: The last 30 years. *Archives of Internal Medicine*. 1999.
- [47] Farmakiotis D, Kontoyiannis DP. Mucormycoses. *Infectious Disease Clinics of North America*. 2016.
- [48] Chander J, Kaur M, Singla N, et al. Mucormycosis: Battle with the deadly enemy over a five-year period in India. *Journal of Fungi*. 2018.
- [49] Patel A, Kaur H, Xess I, et al. A multicentre observational study on the epidemiology of mucormycosis in India. *Clinical Microbiology and Infection*. 2020.
- [50] Lewis RE, Kontoyiannis DP. Epidemiology and treatment of mucormycosis. *Future Microbiology*. 2013.